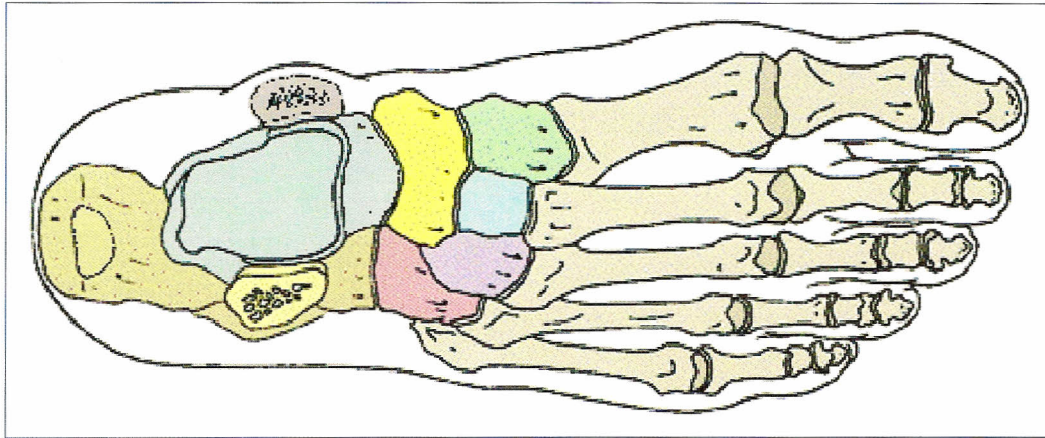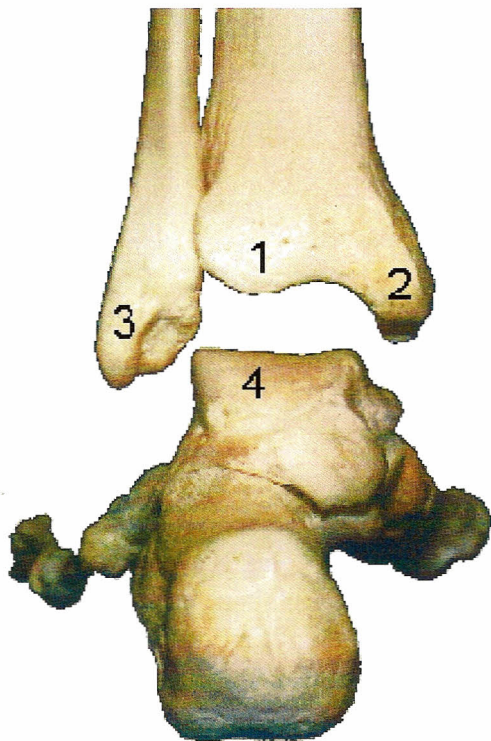
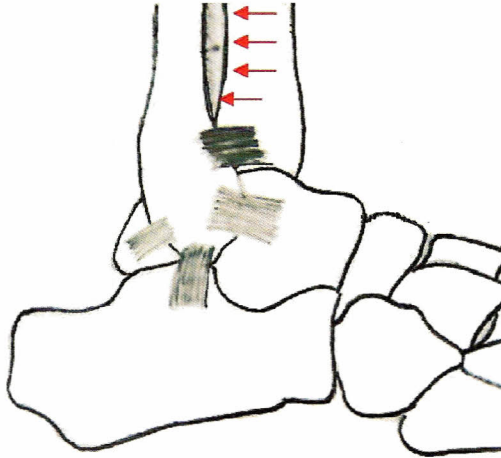


Label all tarsals, label fibula, tibia, 3<sup>rd</sup> metatarsal, 2<sup>nd</sup> proximal phalange, 4<sup>th</sup> distal phalange,



Identify # 1-4

Name the three joints of the ankle and label them. Also describe the movement (if any) that occurs at each joint.

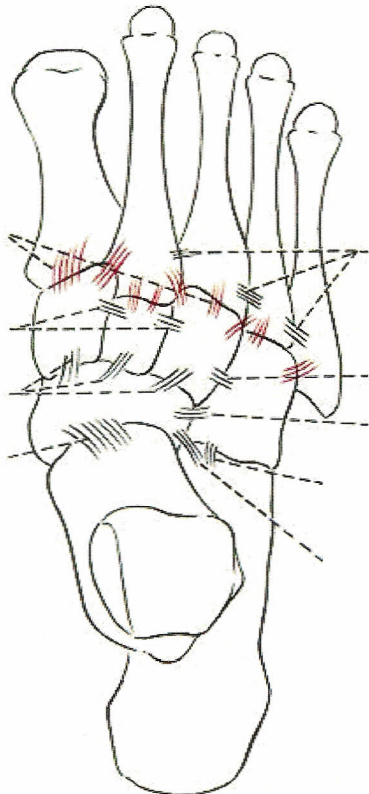


Label all four ligaments in this picture

Which joint is the red arrow pointing to?

Which ligament is supporting that joint?

What is the gray area in between the tibia and fibula?



Is this a dorsal or plantar view?

Label the following 6 joints

- Talocalcaneonavicular
- Calcaneocuboid
- Cuboideonavicular
- Intercuneiform
- Cuneocuboid
- Cuneonavicular

Identify the ligaments on the picture!

Dorsal Intercuneiform Ligaments

Dorsal Cuneocuboid Ligaments

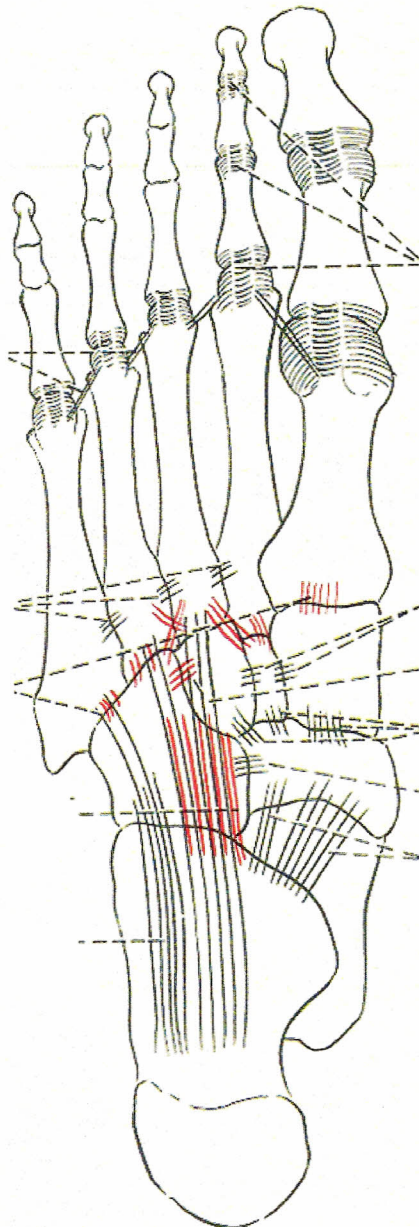
Dorsal Cuneonavicular Ligaments

Taloeonavicular

Dorsal Metatarsal Lig

Dorsal cuboideonavicular ligament

Talocalcaneo ligament



Which Bones Make up the Rear (Hind) foot?

Which Bones make up the Mid Foot?

Which Bones make up the fore foot?

Identify the following ligaments & Joints  
Plantar Calcaneonavicular (Spring Ligament)

**Bifurcate (2 parts)**

**Calcaneonavicular**

**Calcaneocuboid**

Plantar Calcaneocuboid

Long Plantar Ligament

Plantar Metatarsal Lig

Intermetatarsal Joint

Plantar Metatarsal Lig

MTP Joints

Plantar Ligament

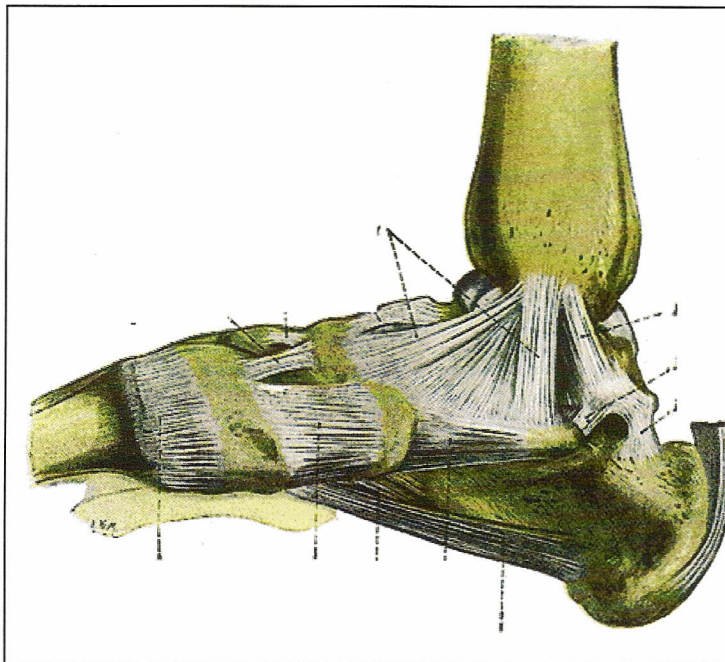
MCL and LCL

Interphalangeal Joints PIP & DIP

Plantar ligament

MCL and LCL





The following is a view of which arch?

Label the following ligaments that support this arch

Deltoid

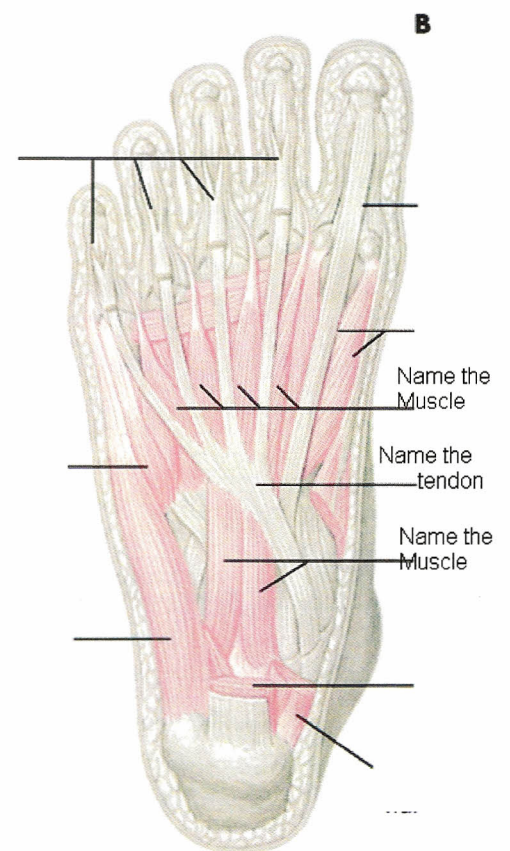
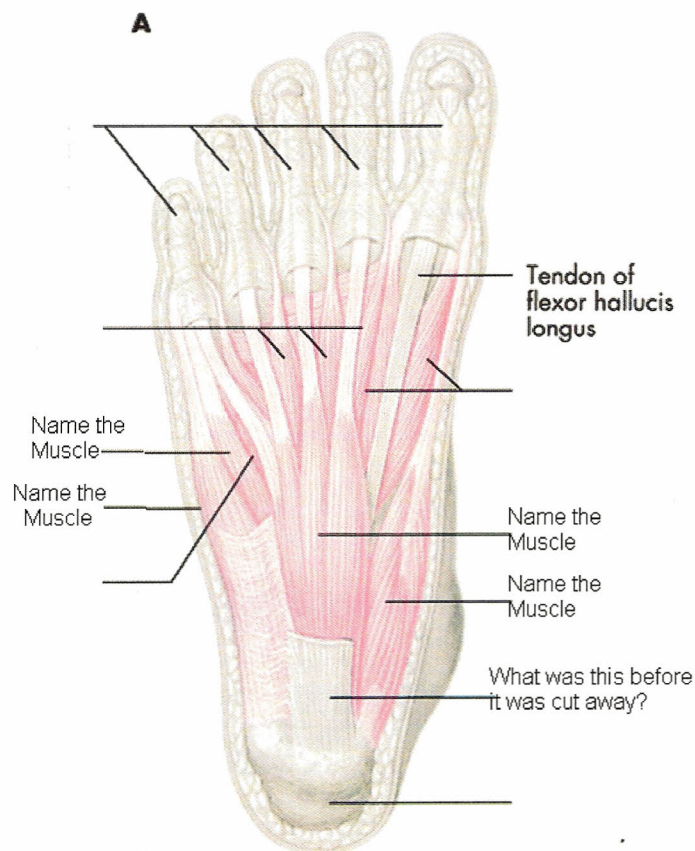
Long Plantar Ligament

Plantar Calcaneonavicular

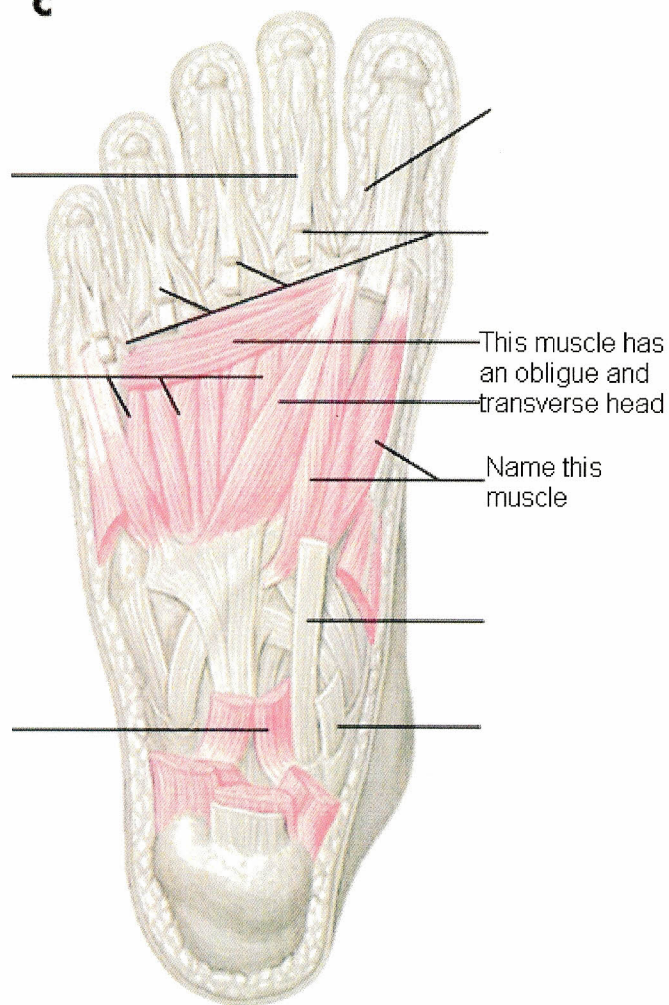
Which three extrinsic Muscles Support this arch?

Which 2 intrinsic muscles help support the arch?

Name the other two arches in the foot



**C**



**D**

